

Case Report

Interstitial Duplication and Distal Deletion in a Ring Chromosome 13 with Pulmonary Atresia and Ventricular Septal Defect: A Case Report and Review of Literature

Fang Xu, PhD;* Autumn J. DiAdamo, BS; Brittany Grommisch, BS; Peining Li, PhD

Department of Genetics, Yale University School of Medicine, New Haven, CT

We report on a newborn female infant with a unique ring chromosome 13. Prenatal findings include intrauterine growth restriction (IUGR); ventricular septal defect (VSD), overriding aorta, and pulmonary stenosis. Postnatal examination found mild dysmorphic features of flat fontanel and hypertelorism. Echocardiogram confirmed the diagnosis of Tetralogy of Fallot (TOF), pulmonary atresia (PA) and VSD. Cytogenetic analysis detected a mosaic pattern of a ring chromosome 13, monosomy 13 and dicentric ring chromosome in about 90%, 9% and 1% of blood lymphocytes, respectively. Oligonucleotide array comparative genomic hybridization (aCGH) analysis revealed a 28.476 Mb interstitial duplication of 13q14.11-q21.33 and a 10.217 Mb distal deletion of 13q33.2-q34. Review of the literature suggested three groups of ring chromosome 13 with variable phenotypes based on the size of 13q deletions and noted two cases of ring chromosome 13 with a distal deletion defined by genomic analysis. A heat map of ring chromosome 13 phenotypes was constructed. The present case represents a new group of ring chromosome 13 with compound segmental duplication and deletion. This study demonstrates the importance of genomic characterization of constitutional ring chromosome for better disease classification and phenotype correlation.

[N A J Med Sci. 2013;6(4):208-212. DOI: 10.7156/najms.2013.0604208]

Key Words: Ring chromosome 13, duplication and deletion, pulmonary atresia, ventricular septal defect

INTRODUCTION

General clinical feature of growth retardation has been related with ring chromosome instability through mitotic cell cycle.¹ Other variable clinical manifestations of a constitutional ring chromosome are likely explained by segmental deletions or duplications from the ring formation. Since the first report of ring chromosome 13 in 1968, its incidence was estimated to be 1 in 58,000 and a syndromic phenotype of mental retardation, microcephaly, craniofacial dysmorphisms, and hand and foot abnormalities had been described.²⁻³ Other variable clinical features were grouped into three clinical entities based on the breakpoints at distal 13q33-q34, intermediate 13q31-q32 and proximal 13q21 bands.⁴ However, a systematic review of clinical and cytogenetic findings from 23 reported cases confirmed the presence of common phenotype but the classification based on G-band breakpoints was controversial.⁵ Since then, there were 20 reports of ring chromosome 13 from the PubMed literature: fourteen cases presented with cytogenetic findings,⁶⁻¹⁶ two reports focused on ocular abnormalities,^{17,18} one report emphasized on skin

pigmentation,¹⁹ one report had congenital coagulation,²⁰ and two recent cases defined the breakpoints using current genomic technologies.^{21,22} Of these over 40 cases of ring chromosome 13, all the earlier reported cases lacked genomic mapping of the ring chromosome structure. This limitation likely explains partly the inconsistency in disease classification and the inaccuracy for phenotype correlations. Genome-wide oligonucleotide array comparative hybridization (aCGH) has been validated for clinical diagnosis and proven to be highly effective in defining the breakpoints and gene content of ring chromosome abnormalities.^{23,24} In this report, we present the first ring chromosome 13 with a unique interstitial duplication and distal deletion. Review of previously reported cases of ring chromosome 13 and recent cases of 13q deletions and duplications provide a heat map of ring chromosome phenotype and a list of potential candidate genes. This case demonstrated the importance of genomic analysis for a better understanding of ring chromosome structure and phenotype correlation.

CASE REPORT

The female infant was born at 37-5/7 gestational weeks through elective cesarean section to a 31 year-old gravid 5, para 3 woman. Pregnancy was complicated by intrauterine growth restriction (IUGR) and prenatally diagnosed

Received 09/24/2013; Revised 10/14/2013; Accepted 10/16/2013

*Corresponding Author: Laboratory of Molecular Cytogenetics and Genomics, Department of Genetics, Yale University School of Medicine, 333 Cedar Street, New Haven, CT 06520-8005. Tel: 203-785-6317; Fax: 203-785-7342. (Email: fang.xu@yale.edu)

ventricular septal defect (VSD), overriding aorta, and pulmonary stenosis. Labor and delivery was uncomplicated. Birth weight was 1,710 g (less than 5th percentile), length was 44 cm (< 5th percentile) and head circumference was 27 cm (<<5th percentile). Apgar scores were 7 and 8 at 1 and 5 minutes, respectively. Physical exam shortly after birth noted hypotonia, mild dysmorphism of flat face and hypertelorism, normal palate, wide spaced nipples, heart murmur with loud second heart sound click, and normal appearances of body extremities. There were no abnormalities in skin pigmentation, genitalia and anus. Echocardiogram confirmed the diagnosis of Tetralogy of Fallot (TOF), pulmonary atresia (PA) and VSD, and demonstrated that there is discontinuous pulmonary blood supply most likely supplied by major aorto-pulmonary collateral arteries (MAPCAs). Brain MRI is normal. Both parents are healthy and elected not to participate in the follow up cytogenetic evaluation.

Chromosome analysis was performed on culture stimulated lymphocytes of peripheral blood from this patient. Of the 100 metaphases examined, a ring chromosome 13 was noted in eighty-eight cells, loss of one chromosome 13 was seen in seven cells and a dicentric ring 13 was found in five cells (**Figure 1A**). The karyotype is: mos 46,XX,r(13)[88]/45,XX,-13[7]/46,XX,dic r(13)[5]. FISH test

was performed using dual color probes for the RB1 gene at 13q14 and the D13S1825 locus at 13q34 (Vysis Inc). Of the 100 nuclei examined, 90% showed three signals for the RB1 probe and one signal for the D13S1825 probe, 9% had one signal for both probes and 1% had five signals for the RB1 probe and one signal for the D13S1825 probe; examination of fifteen metaphases noted two RB1 signals and no D13S1825 signal on the ring chromosome 13 in thirteen cells and a loss of ring chromosome 13 in two cells (**Figure 1A-1B**). The FISH finding is denoted as: nuc ish (RB1x3,D13S1825x1)[90]/(RB1,D13S1825)x1[9]/(RB1x5,D13S1825x1)[1] and ish r(13)(RB1x2,D13S1825x0)[13/15]. Oligonucleotide aCGH analysis using SurePrint G3 Human CGH 4x180K Oligo Microarray Kit (Agilent Technologies Inc, Santa Clara, CA) revealed an XX female with a 28.476 Mb interstitial duplication of 13q14.11-q21.33 (chr13:43,174,874-71,650,688) including genes from TNFSF11 to SCA8 and a 10.217 Mb distal deletion at 13q33.2-q34 (chr13:104,887,988-115,105,297) including genes from DAOA to ZNF828 (**Figure 1C**). Chromosome and FISH analyses observed mitotic instability with a loss of the ring chromosome 13 in 7% of cultured metaphases and 9% of interphase nuclei; aCGH and FISH results indicated that the chromosomally observed ring chromosome 13 contains a large interstitial duplication and a distal deletion.

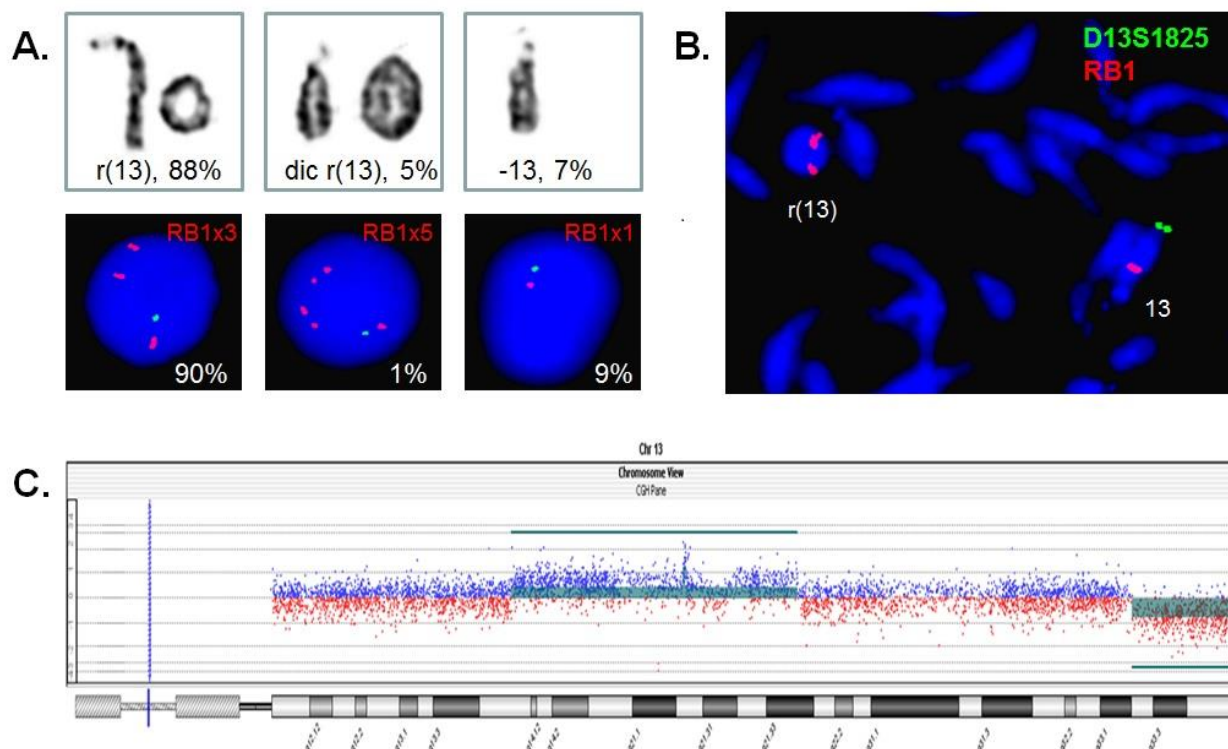


Figure 1. Results from cytogenomic analyses. **A:** Chromosome analysis observed ring 13, dicentric ring 13 and monosomy 13 in 88%, 5% and 7% of metaphases; FISH analysis showed ring 13, dicentric ring 13 and monosomy 13 in 90%, 1% and 9% of interphases. **B:** FISH analysis on metaphases showed two RB1 signals and no D13S1825 signal in the ring chromosome 13. **C:** aCGH reveals a 28.476 Mb duplication of 13q14.11-q21.33 (chr13:43,174,874-71,650,688) and a 10.217 Mb deletion of 13q33.2-q34 (chr13:104,887,988-115,105,297).

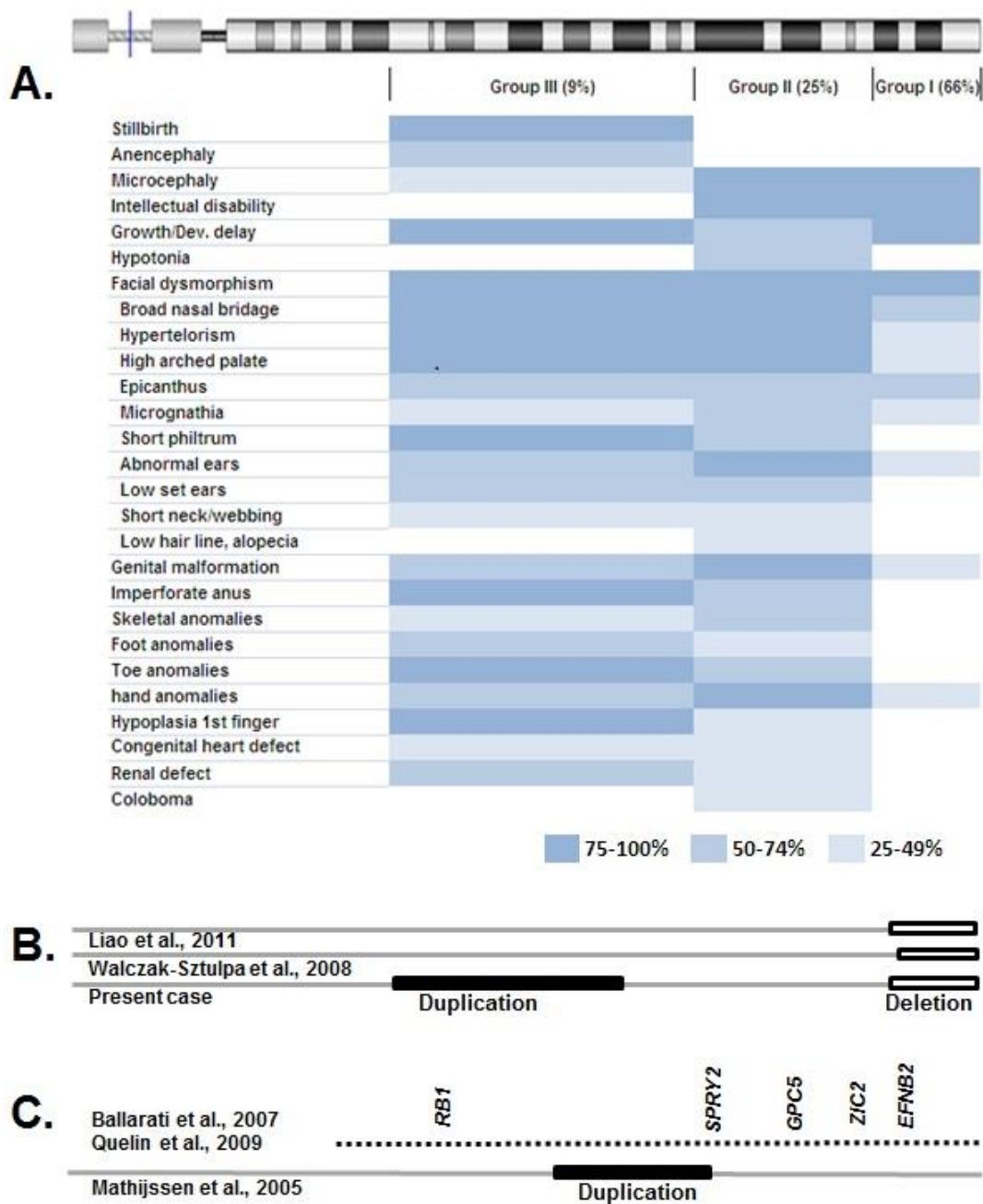


Figure 2. Ring chromosome 13 classification and phenotype correlation. **A:** A heat map showing major clinical features associated with the three groups of ring chromosome 13. **B:** Deletions and duplications detected in ring chromosome 13 by genomic analysis. **C:** Critical intervals and potential candidate genes from defined 13q deletions and duplications. Open box: deletion; filled box: duplication.

DISCUSSION

The ring chromosome 13 had been classified into three groups based on the 13q breakpoints. The group I had breakpoints from 13q33 to 13q34. There were 14 cases in a previous review⁵ and seven cases with detailed cytogenetic and clinical findings afterward.^{9,12,14,16,18,21,22} Of the 21 cases, 80%-100% presented microcephaly, intellectual disability, growth retardation, and facial dysmorphisms of broad nasal bridge, epicanthus, hypertelorism, micrognathia and high arch palate, and 38% had genital malformation from

microorchidism, bifid scrotum, hypospadias to penoscrotal transposition (**Supplemental Table 1,* Figure 2A**). One familial case with a stable ring chromosome 13 in the mother and her daughter showed microcephaly, delayed language and fine motor skills and unremarkable facial features.¹⁴ One case with monoallelic pattern at D13S259 (104.3 Mb at 13q33.1) and biallelic D13S277 (106.2 Mb at 13q33.2) might involve multi breakpoints ring formation.⁹ Two recent cases had defined breakpoints at 104.8 Mb at 13q33.2.^{21,22} The

group II had breakpoints from 13q31 to 13q32. There were six reviewed cases and two more case reports.⁵⁻⁷ Of these eight cases, 80%-100% showed microcephaly, intellectual disability, facial dysmorphism, genital malformation and hand anomalies, and 50%-79% had growth retardation, hypotonia, imperforate anus, skeletal anomalies and toe anomalies (**Supplemental Table 1,* Figure 2A-2B**). The group III had breakpoints from 13q12 to 13q22. There were only three stillbirth cases with severe interuterine growth retardation, facial dysmorphisms, anencephaly, genital malformation and other anomalies (**Supplemental Table 1,* Figure 2A**).⁵ A heat map correlating clinical features with these three groups is shown in **Figure 2**. The present case with interstitial duplication and distal deletion in a ring chromosome 13 represents the group IV of ring chromosome 13 involving complex rearrangement; its clinical features are due to the compound effects of the ring chromosome instability and the segmental trisomy and monosomy. This type of complex ring chromosome structure had been reported through genomic analysis of ring chromosome 21 and a two- or three-step asymmetric breakage and fusion mechanism of ring formation was proposed.²⁴ Additionally, other chromosomal structural variants included two cases showing a small ring chromosome of 13p11-q14 and a derivative chromosome 13 with duplicated 13q14-qter^{10,11} and one case with a supernumerary neocentric ring of 13q31.1-q32.3 derived from an interstitial 13q deletion.¹⁵ Since the group III cases of simple ring chromosome 13 with breakpoints at 13q14 all ended with stillbirth, it seems that the coexistence of small ring chromosome of 13p11-q14 with a derivative chromosome of duplicated distal 13q had made it compatible with life. Prenatal cases of ring chromosome 13 with sonographic detected anencephaly and holoprosencephaly have been reported.^{10,13}

The presence of segmental deletion and duplication within a constitutional ring chromosome and absence of genomic mapping of ring chromosome 13 for most of the previously reported cases likely explains the inaccuracy of disease classification and inconsistency of phenotypic findings. Clinical features were reviewed from cases with 13q segmental deletions and duplications defined by genomic analysis. Two reports with a series of cases of 13q deletions defined by BAC clone FISH and aCGH mapped critical intervals and potential haploinsufficient candidate genes.^{25,26} Deletions containing the EFNB2 gene at 13q33.3 may be involved in eye malformations of microphthalmia, coloboma and retinal dysplasia. The ZIC2 gene at 13q32.3 may be related to brain anomalies. The GPC5 gene at 13q31.3 may be associated with limb defect. The SPRY2 gene at 13q31.1 may be involved in cataracts. The RB1 gene at 13q14.2 is a known risk factor for retinoblastoma. In contrast, only one case with an interstitial duplication of 13q21.3-q31.1 with milder intellectual disability and hyperactivity was reported in a three generation family with six affected patients.²⁷ A deletion and duplication map of 13q is included in Figure 2c. Since the two male cases with defined breakpoints at 13q33.2 showed genital anomalies but not heart defects,^{21,22} it is reasoned there may be haploinsufficient genes for male genital development. The familial case of interstitial

duplication of 13q21.3-q31.1 showed no heart defect.²⁷ Therefore, the heart defect in our patient may be caused by triple-sensitive genes within 13q14.11-q21.3 (43-63 Mb). However, compound effects from the interstitial duplication and distal deletion cannot be ruled out.

In summary, we present the first case of ring chromosome 13 with a 28.476 Mb interstitial duplication of 13q14.11-q21.33 and a 10.217 Mb distal deletion at 13q33.2-q34. This case likely represents a new group of ring chromosome 13. More clinical and cytogenomic studies are warranted to determine the relative frequency of different groups of ring chromosome 13 and their correlated phenotypes.

CONFLICT OF INTEREST

None.

*SUPPLEMENTAL TABLE

Not shown due to the limit of space. Please visit journal website to view: <http://www.najms.net/v06i04p208s01h>.

REFERENCES

- Kosztolányi G. Does "ring syndrome" exist? An analysis of 207 case reports on patients with a ring autosome. *Hum Genet.* 1987;75(2):174-179.
- Lejeune J, Lafourcade J, Berger R, et al. Le phénotype (Dr): étude de trois cas de chromosomes D en anneau. *Ann Genet (Paris).* 1968;11(2):79-87.
- Martin NJ, Harvey PJ, Pearn JH. The ring chromosome 13 syndrome. *Hum Genet.* 1982; 61(1):18-23.
- Niebuhr E, Ottosen J. Ring chromosome D (13) associated with multiple congenital malformations. *Ann Genet (Paris).* 1973;16(3):157-166.
- Brandt CA, Hertz JM, Petersen MB, Vogel F, Noer H, Mikkelsen M. Ring chromosome 13: lack of distinct syndromes based on different breakpoints on 13q. *J Med Genet.* 1992;29(10):704-708.
- Guala A, Dellavecchia C, Mannarino S, et al. Ring chromosome 13 with loss of the region D13S317-D13S285: phenotypic overlap with XK syndrome. *Am J Med Genet.* 1997;72(3):319-323.
- Boduroglu K, Alikasifoglu M, Tunçbilek E, Uludogan S. Ring chromosome 13 in an infant with multiple congenital anomalies and penoscrotal transposition. *Clin Dysmorphol* 1998;7(4):299-301.
- Gentile M, Buonadonna AL, Cariola F, Fiorente P, Valenzano MC, Guanti G. Molecular and cytogenetic characterisation of an unusual case of partial trisomy/partial monosomy 13 mosaicism: 46,XX,r(13)(p11q14)/46,XX,der(13)t(13;13)(q10;q14). *J Med Genet.* 1999;36(1):77-82.
- Talvik I, Ounap K, Bartsch O, Ilus T, Uibo O, Talvik T. Boy with celiac disease, malformations, and ring chromosome 13 with deletion 13q32-->qter. *Am J Med Genet.* 2000;93(5):399-402.
- Chen CP, Chern SR, Lee CC, Chen WL, Wang W. Prenatal diagnosis of mosaic ring chromosome 13 with anencephaly. *Prenat Diagn.* 2001;21(2):102-105.
- Morrisette JD, Celle L, Owens NL, Shields CL, Zackai EH, Spinner NB. Boy with bilateral retinoblastoma due to an unusual ring chromosome 13 with activation of a latent centromere. *Am J Med Genet.* 2001;99(1):21-28.
- Venugopalan P, Kenue RK. Ring chromosome 13 in an Omani infant boy with mental retardation and multiple congenital anomalies. *Saudi Med J.* 2001;22(9):800-803.
- Sepulveda W, Dezerega V, Be C. First-trimester sonographic diagnosis of holoprosencephaly: value of the "butterfly" sign. *J Ultrasound Med.* 2004;23(6):761-765.
- Bedoyan JK, Flore LA, Alkatib A, Ebrahim SA, Bawle EV. Transmission of ring chromosome 13 from a mother to daughter with both having a 46,XX, r(13)(p13q34) karyotype. *Am J Med Genet A.* 2004;129A(3):316-320.
- Amor DJ, Voullaire L, Bentley K, Savarirayan R, Choo KHA. Mosaic Monosomy of a neocentric ring chromosome maps brachyphalangy and growth hormone deficiency to 13q31.1-13q32.3. *Am J Med Genet.* 2005;133A(2):151-157.

16. Sankar VH, Phadke SR. Ring chromosome 13 in an infant with ambiguous genitalia. *Indian Pediatr.* 2006;43(3):258-260.
17. Filous A, Rasková D, Kodet R. Retinal detachment in an infant with the ring chromosome 13 syndrome. *Acta Ophthalmol Scand.* 1998;76(6):739-741.
18. Heaven CJ, Lalloo F, Mchale E. Keratoconus associated with chromosome 13 ring abnormality. *Br J Ophthalmol.* 2000;84(9):1079.
19. Fryns JP, Devriendt K, Legius E. Skin pigmentation anomalies in ring chromosome 13. *Genet Couns.* 1998;9(2):155-156.
20. Ruiz Del Prado M, Alfonso Landa J, Cristóbal Navas C, et al. Ring chromosome 13 and congenital coagulation factor deficiency. *An Esp Pediatr.* 2001;54(4):411-412.
21. Walczak-Sztulpa J, Wisniewska M, Latos-Bielenska A, et al. Chromosome deletions in 13q33-34: report of four patients and review of the literature. *Am J Med Genet A.* 2008;146(3):337-342.
22. Liao C, Fu F, Zhang L. Ring chromosome 13 syndrome characterized by high resolution array based comparative genomic hybridization in patient with 47, XYY syndrome: a case report. *J Med Case Rep.* 2011;5:99.
23. Xiang B, Li A, Valentin D, Novak N, Zhao HY, Li P. 2008. Analytical and clinical validity of whole genome oligonucleotide array comparative genomic hybridization for pediatric patients with mental retardation and developmental delay. *Am J Med Genet.* 146A(15): 1942-1954.
24. Zhang HZ, Xu F, Seashore M, Li P. Unique genomic structure and distinct mitotic behavior of ring chromosome 21 in two unrelated cases. *Cytogenet Genome Res.* 2012;136(3):180-187.
25. Ballarati L, Rossi E, Bonati MT, et al. 13q Deletion and central nervous system anomalies: further insights from karyotype-phenotype analyses of 14 patients. *J Med Genet.* 2007;44(1):e60.
26. Quélin C, Bendavid C, Dubourg C, et al. Twelve new patients with 13q deletion syndrome: genotype-phenotype analyses in progress. *Eur J Med Genet.* 2009;52(1):41-46.
27. Mathijssen IB, Hoovers JM, Mul AN, Man HY, Ket JL, Hennekam RC. Array comparative genomic hybridization analysis of a familial duplication of chromosome 13q: a recognizable syndrome. *Am J Med Genet A.* 2005;136(1):76-80.